



## **IAP Neonatology Chapter**

### **IAP Neonatology Fellowship Exam 2021**

#### **Theory Paper 1**

**Time: 3 hours**

**Total Marks–100**

- **Attempt all questions.**
- **Write in legible handwriting.**
- **Write answers to the point.**
- **Quote evidence / studies wherever required.**

**Question 1: Write short notes on the following (20 marks)**

- A. Describe the changes in NRP 8<sup>th</sup> edition in comparison to the 7<sup>th</sup> edition (10)
- B. What do you understand by Intact cord resuscitation? (5)
- C. Discuss the temperature management of an extreme preterm in the delivery room.(5)

**Question 2: Write short notes on the following: (20 marks)**

- A. Rational use of antibiotics in NICU- Why? And how to practice? (5)
- B. Universal newborn hearing screening (5)
- C. Complications of nasal CPAP therapy in neonates and its prevention. (5)
- D. Bundle approach in NICU (5)

**Question 3: Illustrate the following using flow chart (20 marks)**

- A. Management of a neonate born to a COVID 19 positive mother (5)
- B. Diagnosis and management of PPHN (5)
- C. Approach to a neonate with cholestatic jaundice (5)
- D. Staging of Retinopathy of Prematurity and screening protocol (5)

**Question 4: Write short notes on the following (20 marks)**

- A. Quality improvement in NICU (5)



- B. Human milk banking (5)
- C. LaQshya program (5)
- D. Therapeutic hypothermia in LMIC (5)

**Question 5: Choose the most appropriate answer (20 marks - 1 mark for each MCQ)**

- 1. Which of the following is not a component of the biophysical profile?**
  - a. Fetal breathing movements
  - b. Gross body movements
  - c. Doppler of umbilical artery
  - d. Reactive fetal heart rate by nonstress test
  
- 2. Maternal milk is the predominant source of which of the following for preterm infants?**
  - a. Secretory immunoglobulin A.
  - b. Immunoglobulin G.
  - c. Interleukin-6.
  - d. Lysozyme.
  
- 3. A term male infant has cyanosis and respiratory distress after birth. An echocardiogram reveals a diagnosis of pulmonary hypertension. Which of the following maternal medications is associated with pulmonary hypertension in the newborn?**
  - a. Indomethacin
  - b. Lithium
  - c. Nifedipine
  - d. Terbutaline
  
- 4. A patient has a normal fetal anatomy survey at 18 weeks. She decides to have maternal serum quad testing for aneuploidy screening, which shows an elevated risk of trisomy 21. Which of the following is true?**
  - a. The anatomy survey must have overlooked features of trisomy 21 because the false-positive rate of the quad screen is low.
  - b. The quad screen must be a false-positive because no sonographic features of trisomy 21 were detected.
  - c. Diagnostic testing for trisomy 21 should be offered.
  - d. The fetus has trisomy 21
  
- 5. A 10-day-old infant is being treated for sepsis with antibiotics and dopamine. The infant is requiring escalating doses of dopamine. All the interventions below can increase the infant's response to the current dose of dopamine, except for one. Which intervention does not increase an infant's sensitivity to catecholamines?**



- a. Beginning steroid administration
  - b. Normalizing pH
  - c. Normalizing serum calcium levels
  - d. Normalizing potassium levels
6. **A preterm infant born at 26 weeks' gestation is now 3 days old and you are considering initiating trophic enteral feeds. Mom is known to be seropositive for cytomegalovirus (CMV) and she asks you about the risk of transmission of CMV through breast milk and the risk of pneumonia due to CMV. What is your response?**
- a. CMV is eliminated by freeze-thawing process.
  - b. CMV only rarely causes pneumonia, postnatally.
  - c. CMV can cause interstitial pneumonia in preterm infants but can be eliminated by short-term pasteurization.
  - d. Provide preterm formula as the risk of pneumonia is very high.
7. **You are asked to evaluate an infant for hypotonia. You note that the infant has significant hypotonia and feeding difficulties. The mother is well-appearing but has difficulty releasing your handshake. Both the mother and infant are subsequently diagnosed with myotonic dystrophy. The phenomenon described here, where the infant is more severely affected than the mother, is known as:**
- a. anticipation
  - b. imprinting
  - c. mitochondrial inheritance
  - d. uniparental disomy
8. **Several studies have shown that there is a small but definite increase in congenital malformations in neonates following artificial reproductive technology (ART) conception. In which type of ART is an increased incidence of urogenital abnormalities, specifically hypospadias, likely to occur?**
- a. Gamete intrafallopian tube transfer (GIFT)
  - b. Intracytoplasmic sperm injection (ICSI)
  - c. Embryo cryopreservation
  - d. Blastocyst culture
9. **Transplacental transfer of all the following nutrients is by SIMPLE DIFFUSION except:**
- a. Calcium
  - b. Glucose
  - c. Lipids
  - d. Sodium
10. **Which of the statements are true regarding Symmetric IUGR?**
- a. HC percentile greater than weight percentile
  - b. Early onset—prior to 3rd trimester



- c. Results from uteroplacental insufficiency
- d. Blood flow to internal carotid artery is increased

**11. Choose the correctly matched pair**

- a. Deformation – Hemangioma
- b. Malformation – Cleft palate
- c. Dysplasia – Amniotic Bands
- d. Disruption – Arthrogryposis

**12. Which of the following statement regarding surfactant replacement in infants with RDS is true?**

- a. Synthetic surfactant is more effective than natural surfactant.
- b. Surfactant administration reduces the incidence of PDA.
- c. Surfactant proteins enhance spreading of natural surfactant.
- d. Serum proteins enhance surfactant function.

**13. Which of the following therapies decreases bilirubin production?**

- a. Tin-protoporphyrin
- b. Phototherapy
- c. Exchange transfusion
- d. Phenobarbital

**14. Wave V in Auditory Brain stem response originates from**

- a. Superior olive
- b. Inferior colliculus
- c. Medial lemniscus
- d. Lateral lemniscus

**15. Laser photocoagulation is applied to which part of retina in treatment of ROP**

- a. Vascular part of retina
- b. Avascular part of retina
- c. Both vascular and avascular parts of retina
- d. Macula lutea

**16. According to NRP recommendation what is the gestation age (in weeks) below which Plastic bag or plastic wrap is recommended?**

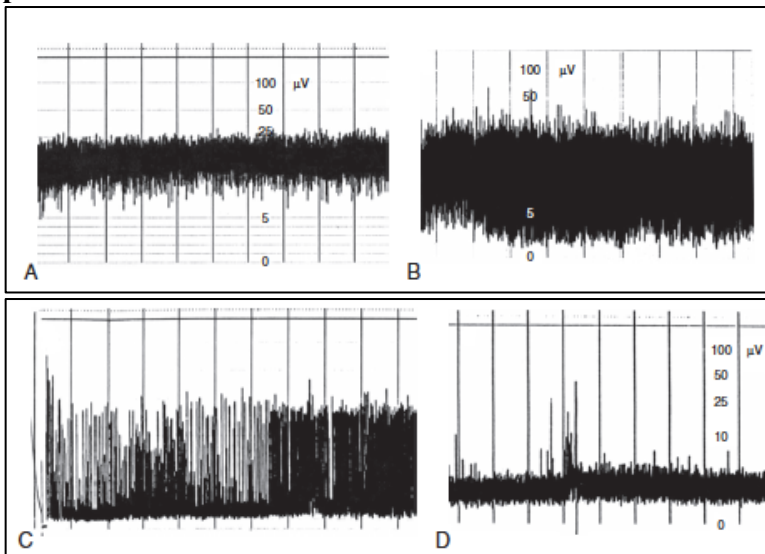
- a. <29
- b. 30
- c. <31
- d. <32

**17. ROC curve is used in which type of study**

- a. Cohort studies

- b. Case control studies
- c. Interventional studies
- d. Diagnostic studies

18. Which of the following amplitude EEG trace is suggestive of burst suppression pattern?



- a. A
- b. B
- c. C
- d. D

19. Correct match is

I. Spastic diplegic CP	a. Severe hyperbilirubinemia
II. Choreoathetoid CP	b. Periventricular leukomalacia
III. Spastic hemiplegic CP	c. Congenial infection
IV. Spastic quadriplegia	d. Perinatal stroke

- a. I-a, II-c, III-b, IV-d
- b. I-b, II-a, III-d, IV-c
- c. I-b, II-a, III-c, IV-d
- d. I-b, II-c, III-a, IV-d

20. Imaging is NOT indicated in which of the following cutaneous lesion associated with occult spinal dysraphism

- a. Hairy patch
- b. Aplasia cutis
- c. Simple dimples
- d. Dermal cyst

